بسم الله الرحمن الرحيم

السلام عليكم ورحمة الله وبركاته

Oral pathology

ULCERATIVE & VESICULOBULLOUS LESIONS OF THE ORAL CAVITY.

Pemphigus vulgaris. Multiple erosions of the left buccal mucosa.

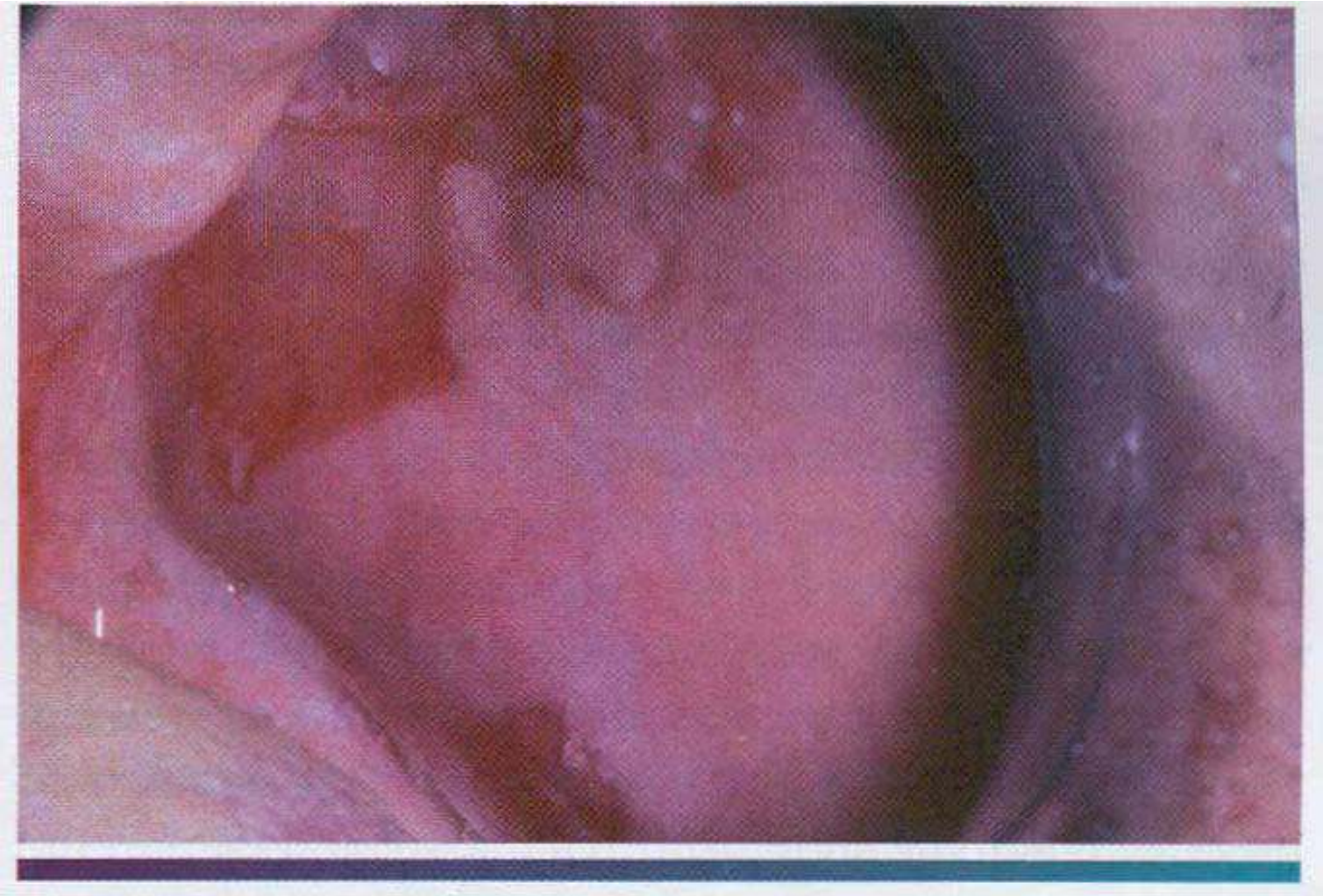

Pemphigus vulgaris. large. irregularly shaped ulcerations involving the floor of the mouth and ventral tongue.

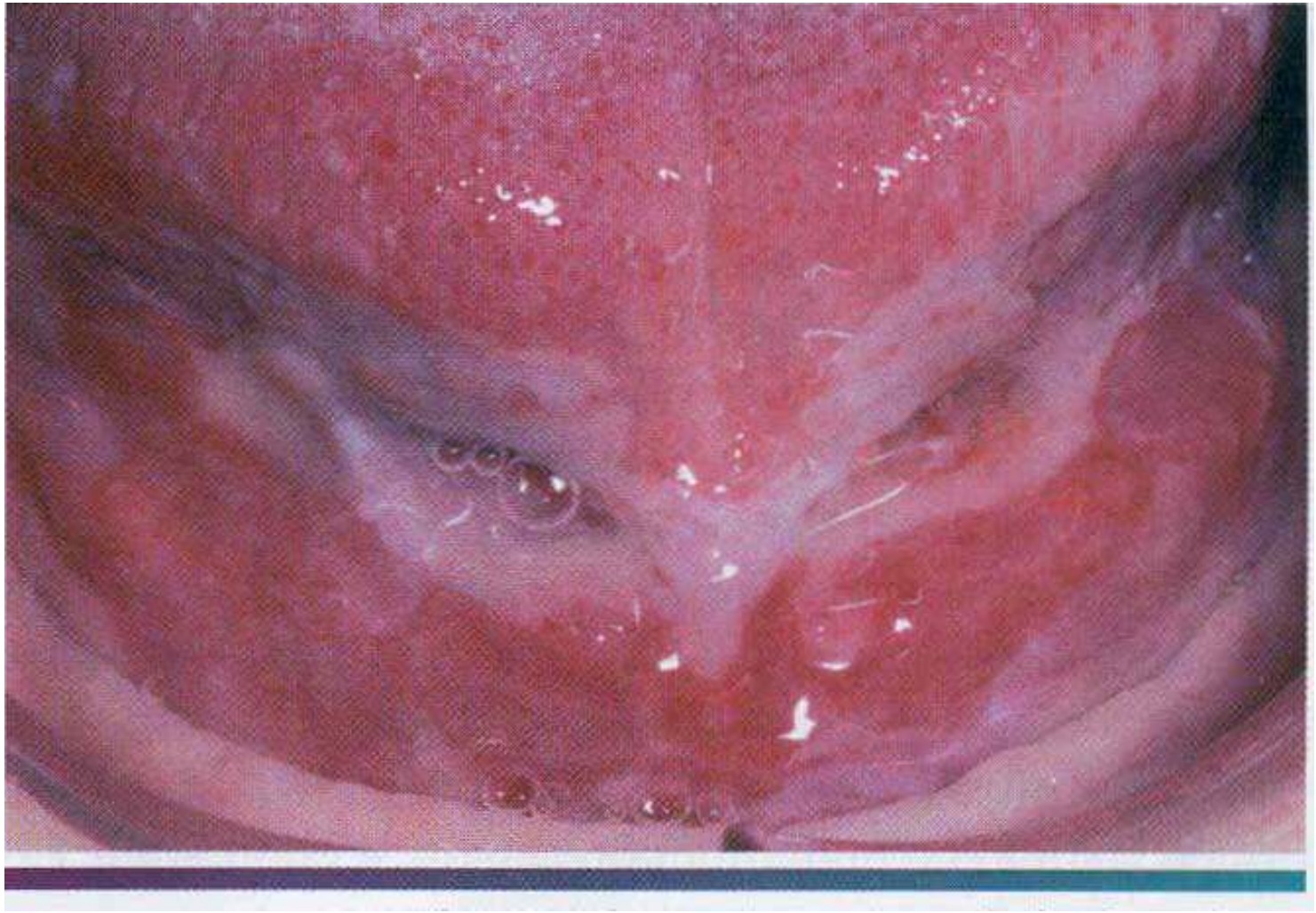

Cutaneous pemphigus vulgaris.

Pemphigus vulgaris. This cutaneous bulla is characteristic of skin involvement.

Oral pemphigus vulgaris, buccal mucosa. Note surface slough with ulceration and bleeding.

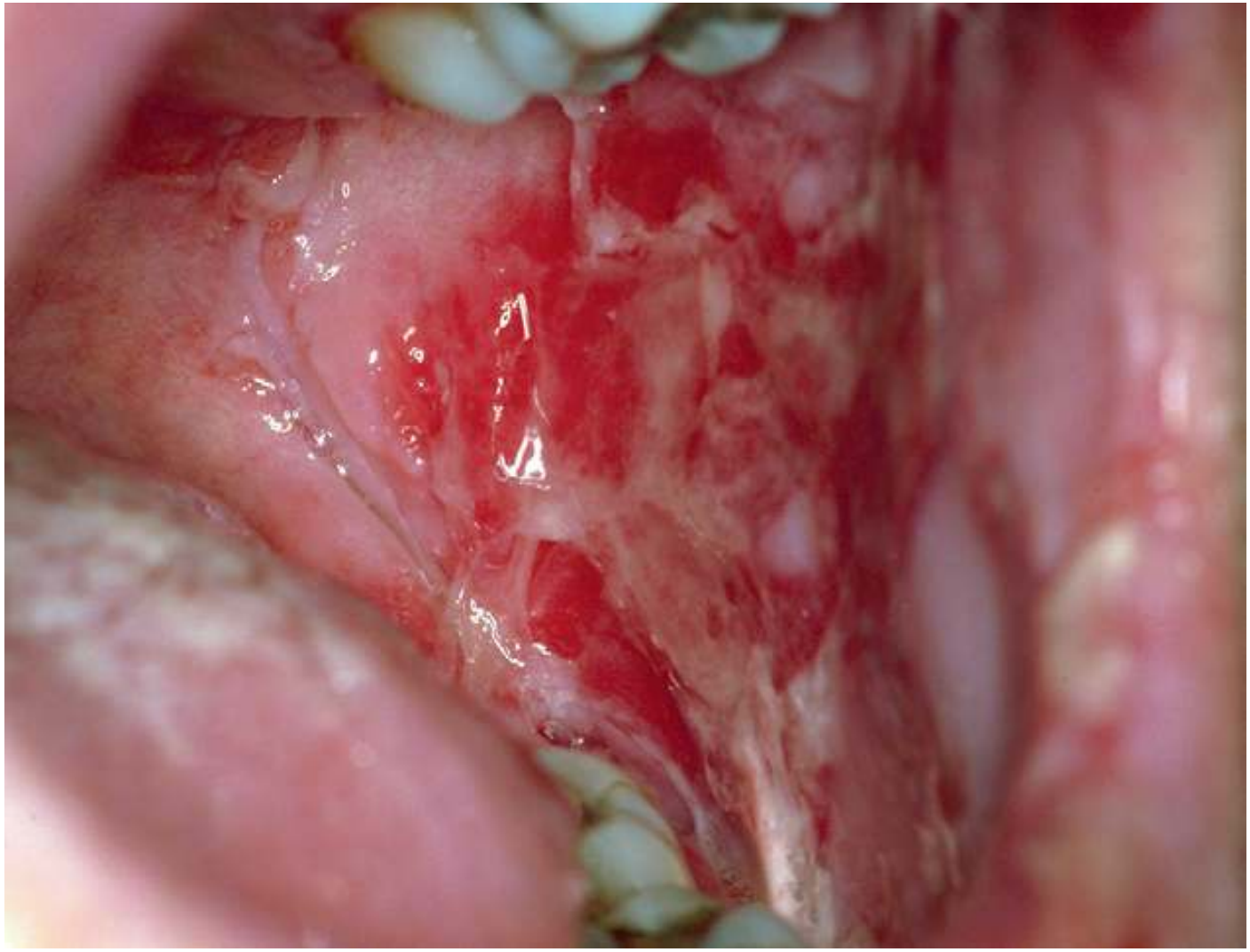

Pemphigus vulgaris of the lower lip.

Pemphigus bulla and ulcers.

Histopathology and Immunopathology:

- Pemphigus vulgaris appears as intraepithelial clefting with keratinocyte **acantholysis** . Loss of desmosomal attachments result in free-f bating, or acantholytic , Tzanck cells.
- Bullae are suprabasal, and the basal layer remains attached to the basement membrane.

Oral pemphigus vulgaris showing intra epithelial separation and Tzanck cells.

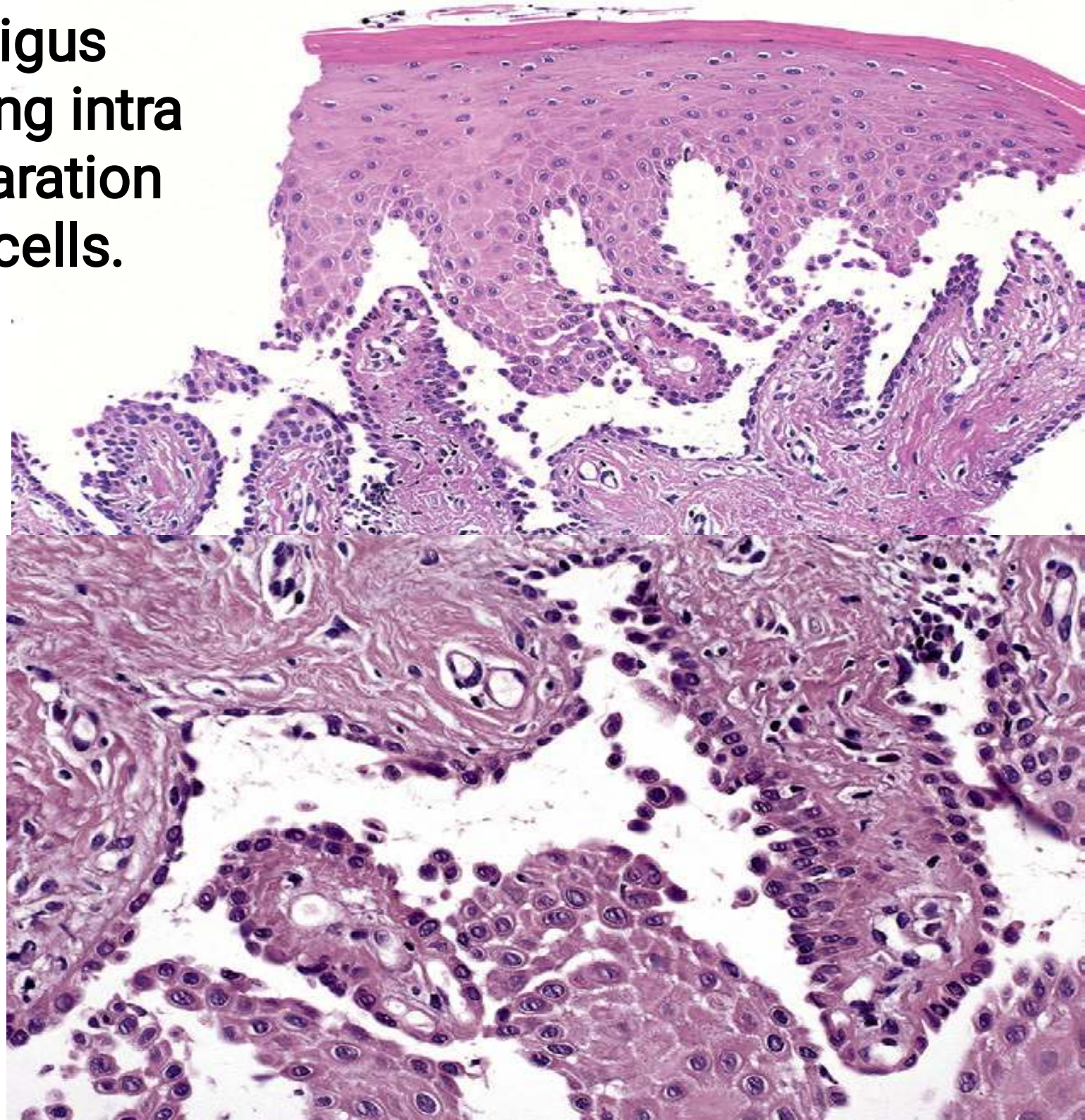

Pemphigus vulgaris.

An intraepithelial cleft is located just above the basal cell layer.

Pemphigus vulgaris. acantholytic epithelial cells sitting within the intraepithelial cleft

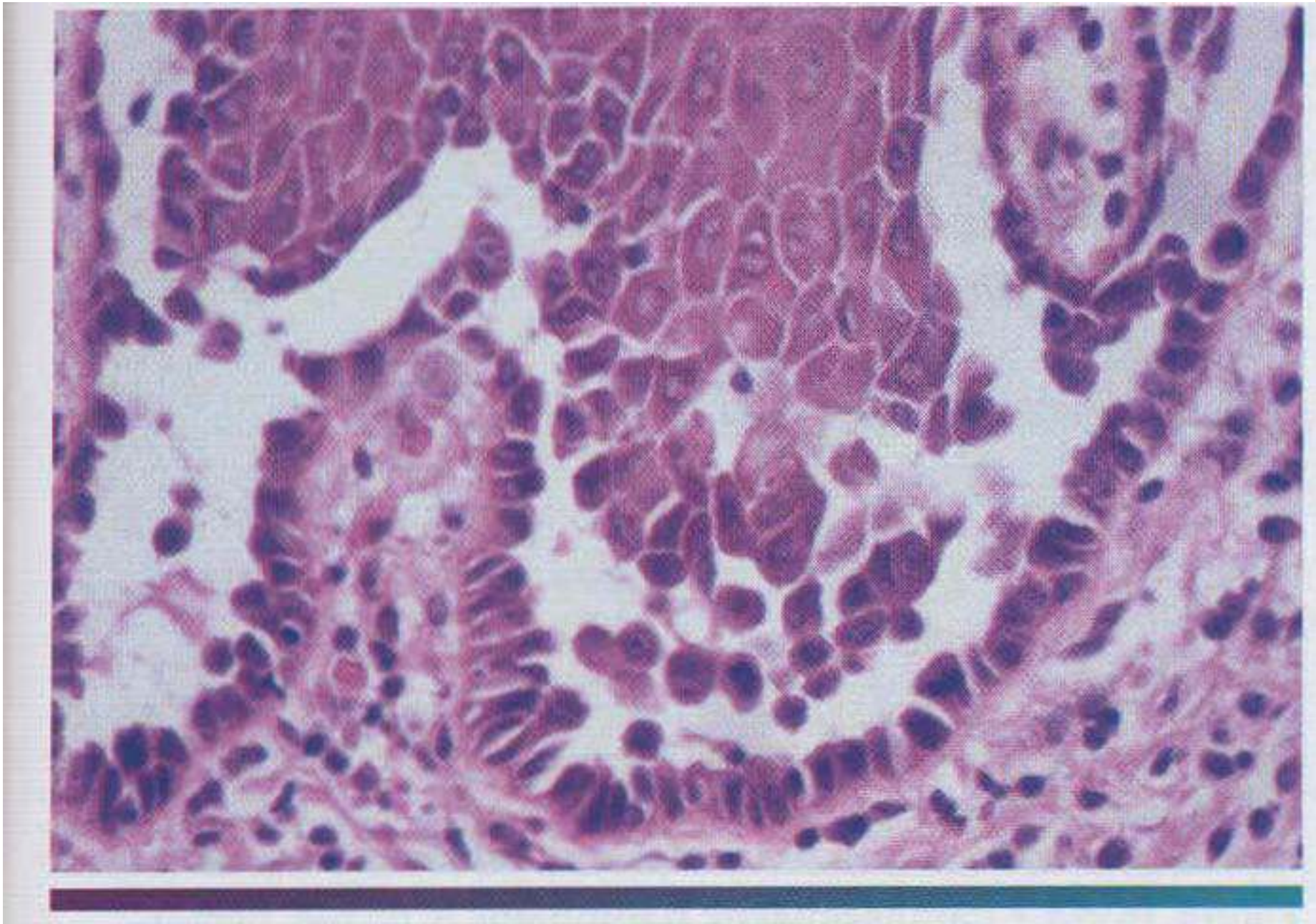

Pemphigus vulgaris; immunofluorescence pattern.

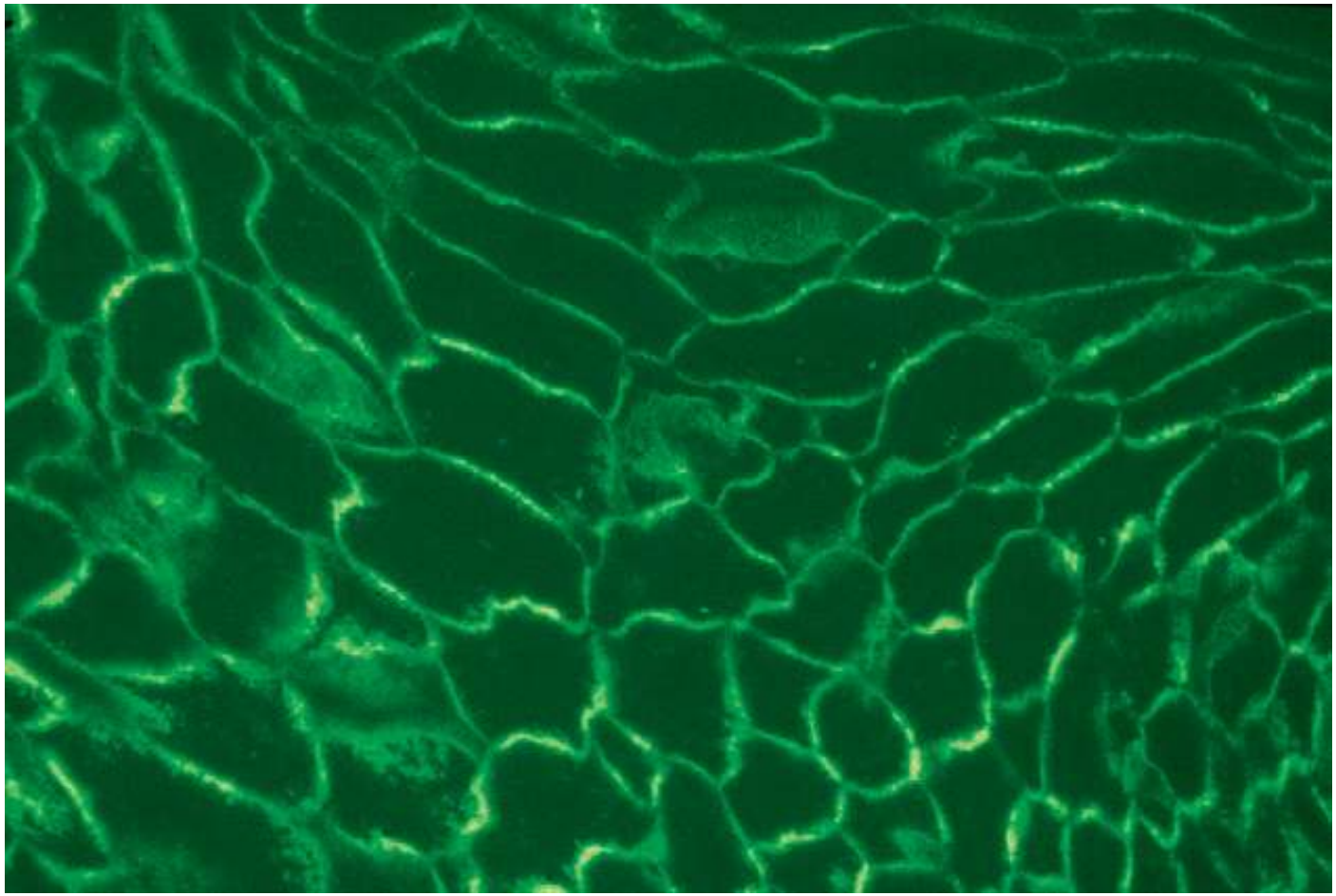

Cicatricial pemphigoid. Although cutaneous lesions are not common, tense bullae such as these may develop on the skin of 20% of affected patients.

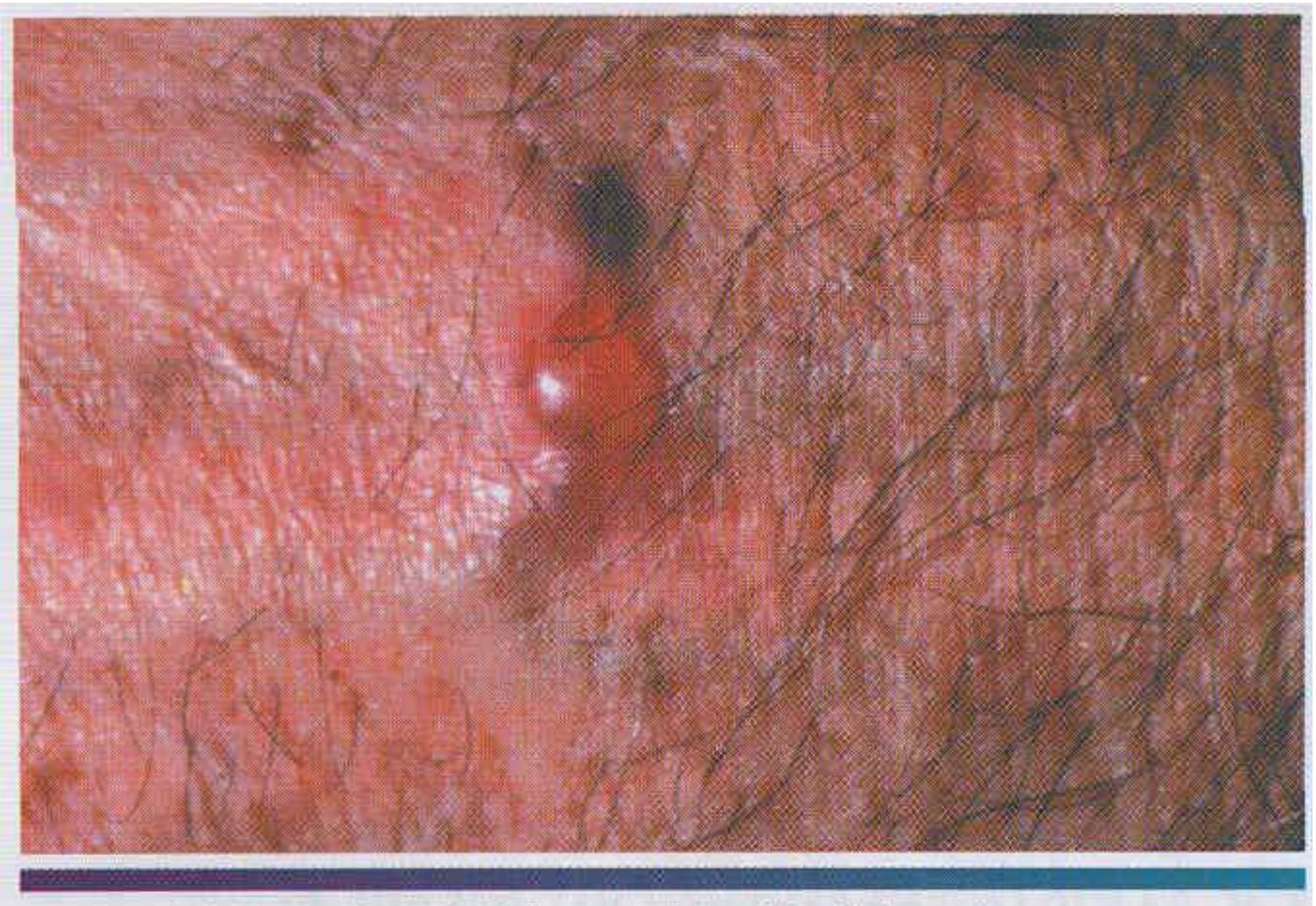

Cicatricial pemphigoid . Often the gingival tissues are the only affected site, resulting in a clinical pattern known asdesquamative gingivitis. Such a pattern may also be seen with lichen planus and pemphigus vulgaris.

Cicatricial pemphigoid. Large, irregular oral ulcerations characterize the lesions after the initial bullae rupture.

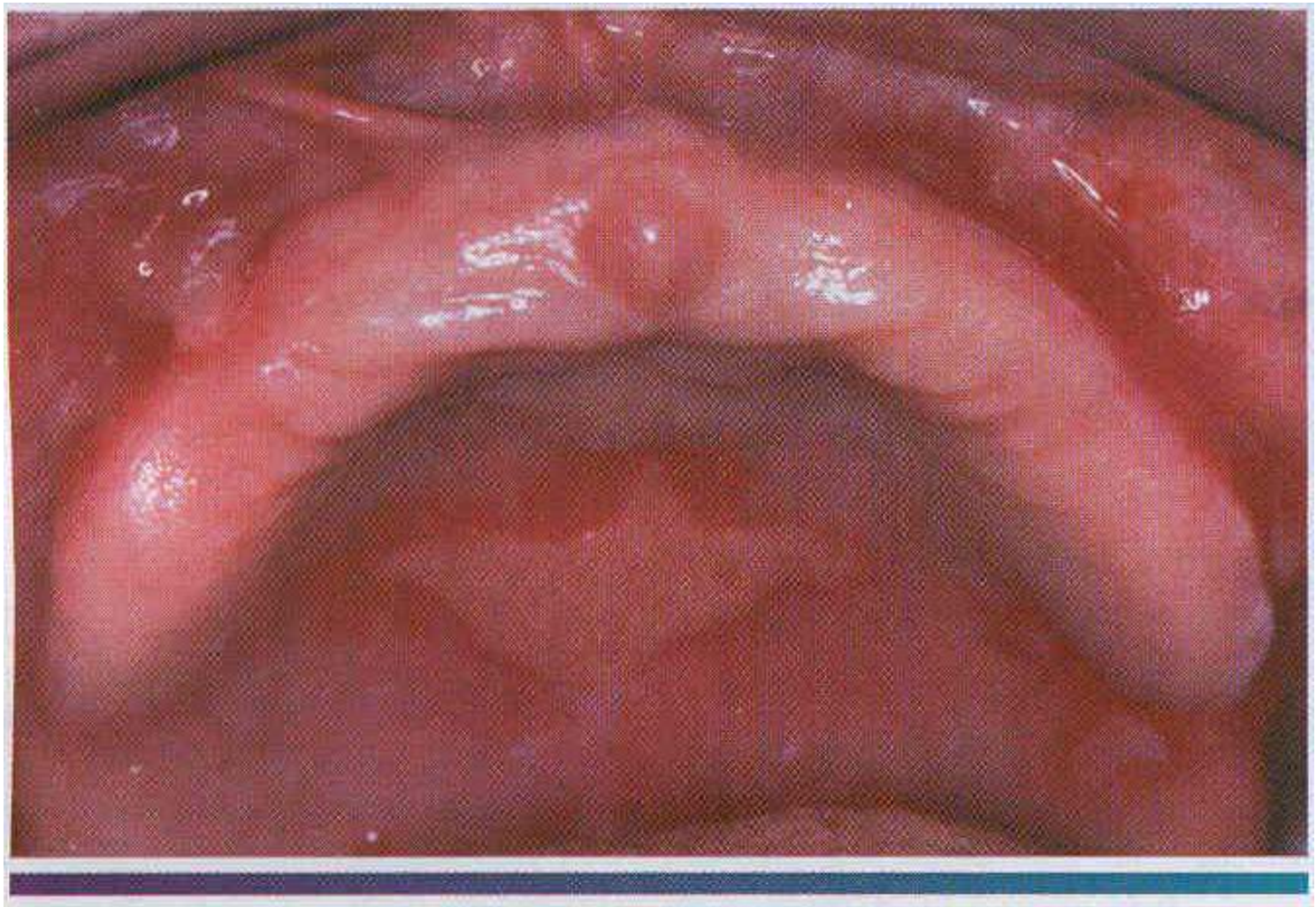

Cicatricial pemphigoid . In this patient, the ocular involvement has resulted in nearly complete scarring between the conjunctival mucosa and the eyelids themselves, producing blindness.

Mucous membrane pemphigoid of the gingiva.

Mucous membrane pemphigoid.

Ocular pemphigoid.

Mucous membrane pemphigoid showing characteristic subepithelial separation.

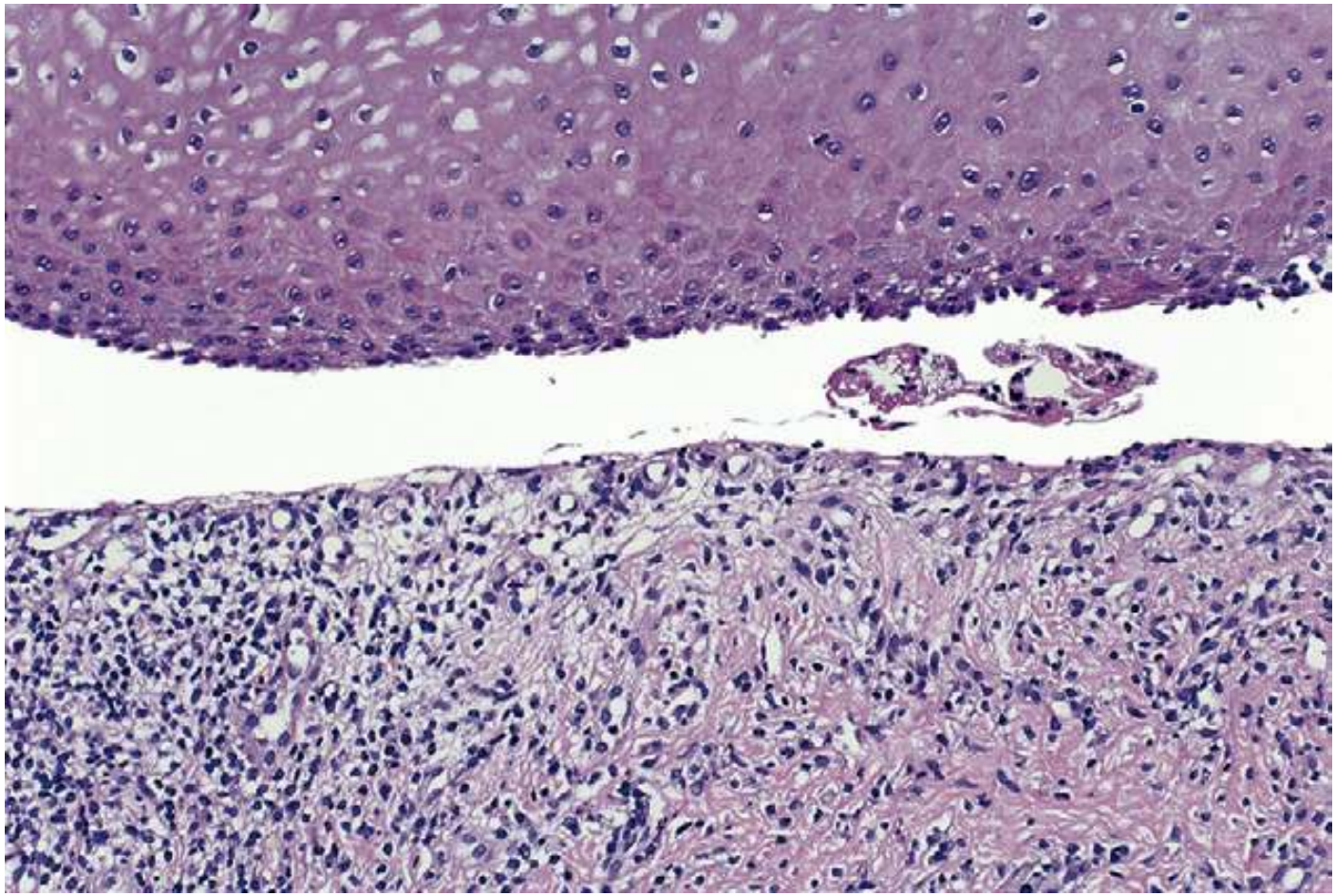

Cicatricial pemphigoid perilesional tissue shows characteristic subepithelial clefting.

Mucous membrane pemphigoid; basement membrane immunofluorescent staining.

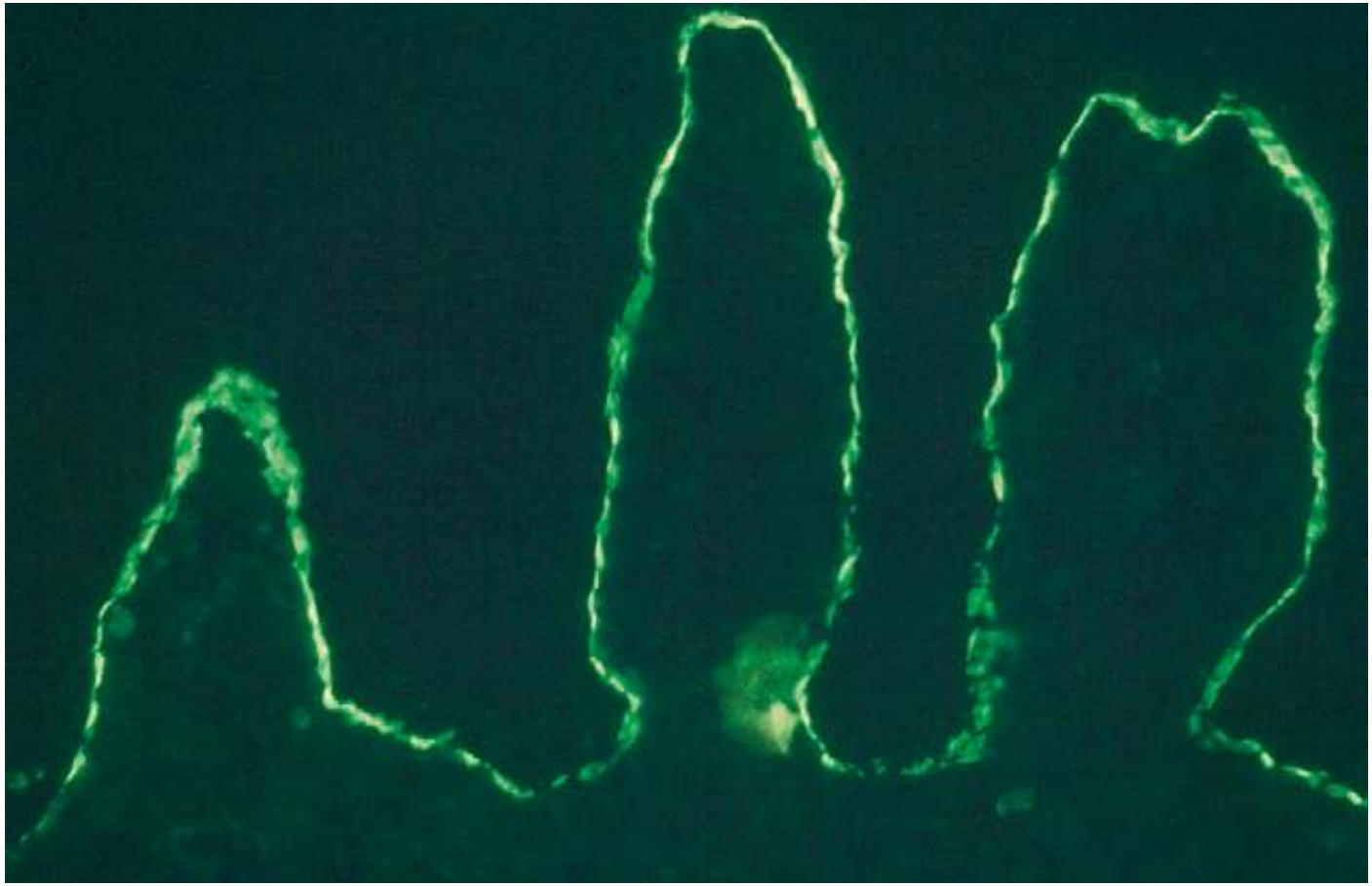

Epidermolysis bullosa in a child. Note ulcers, constricted opening, and atrophic tongue mucosa.

Pemphigus vulgaris presenting as shallow, irregular
red erosions of the ventral tongue with ulcers and tissue tags.

Pemphigus vulgaris presenting as eros
of the
gingiva.

PEMPHIGUS VULGARIS

tazank cells

Bullous pemphigoid resulting in tense skin blisters.

PEMPHGOID

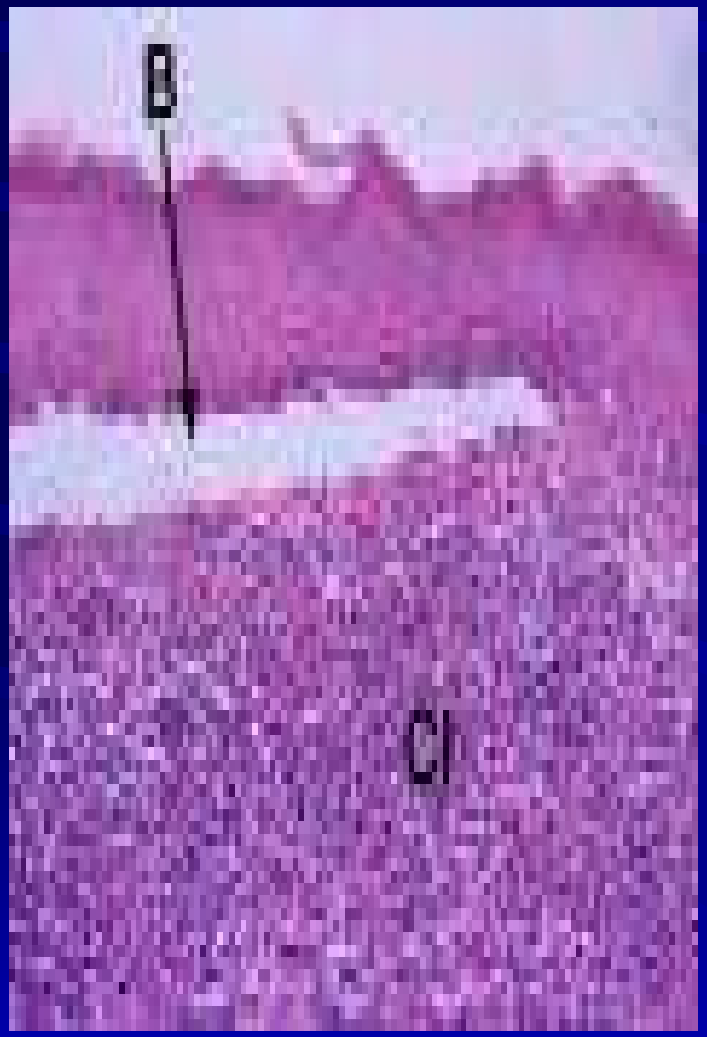

THANK YOU